



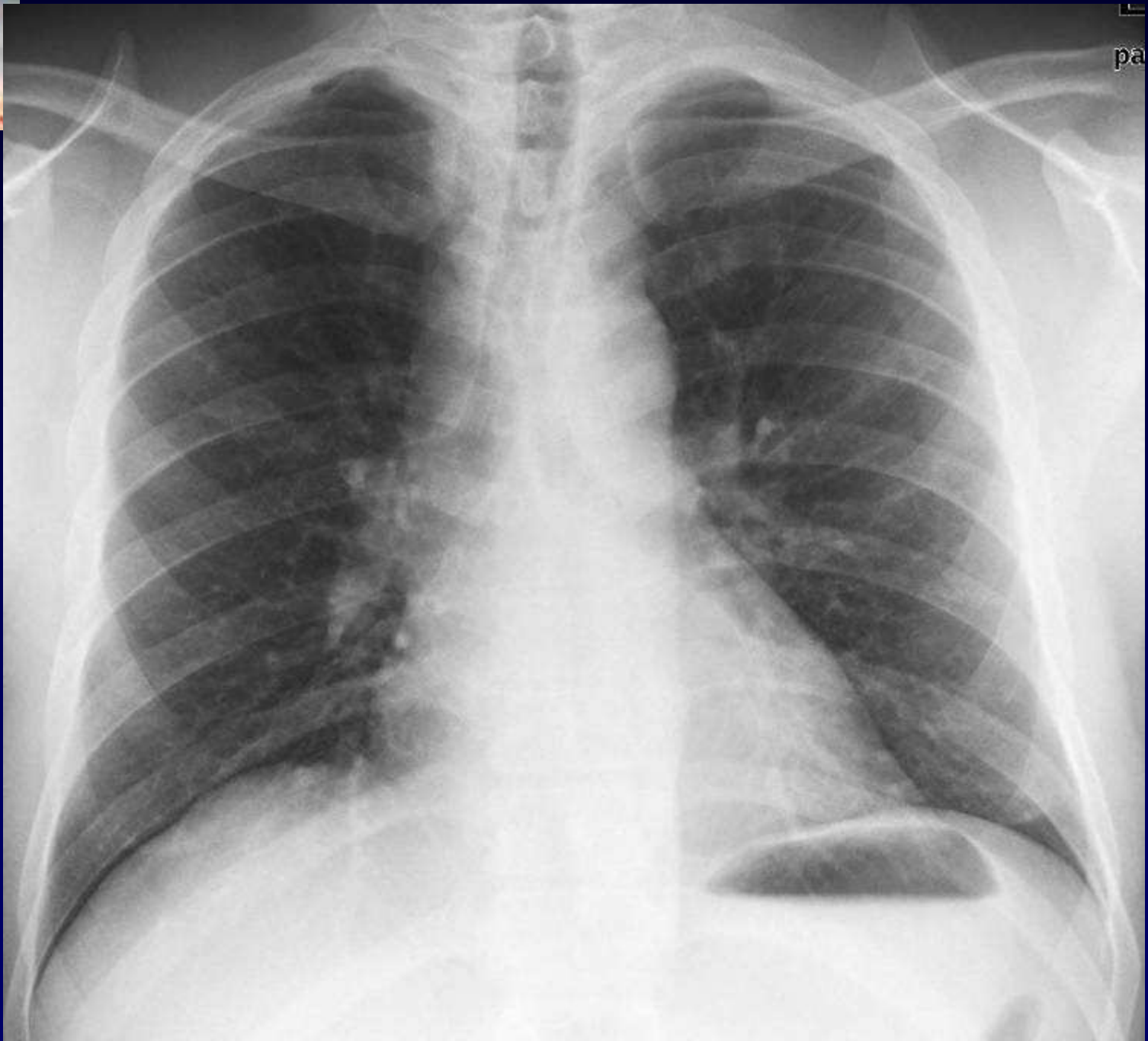
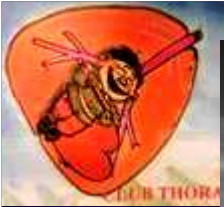Dossier 2

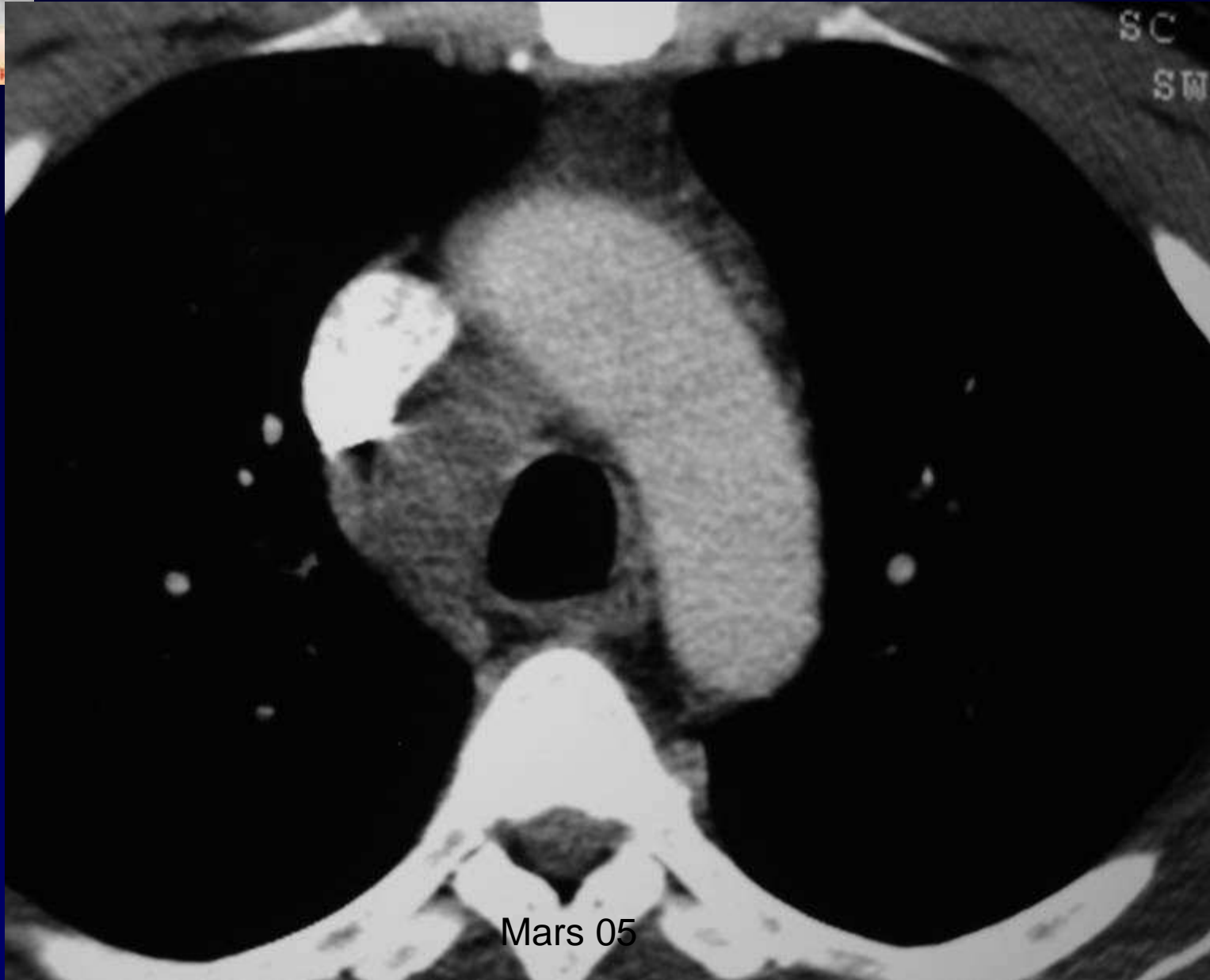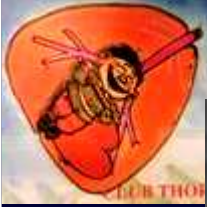MP. Debray

Homme de 31 ans

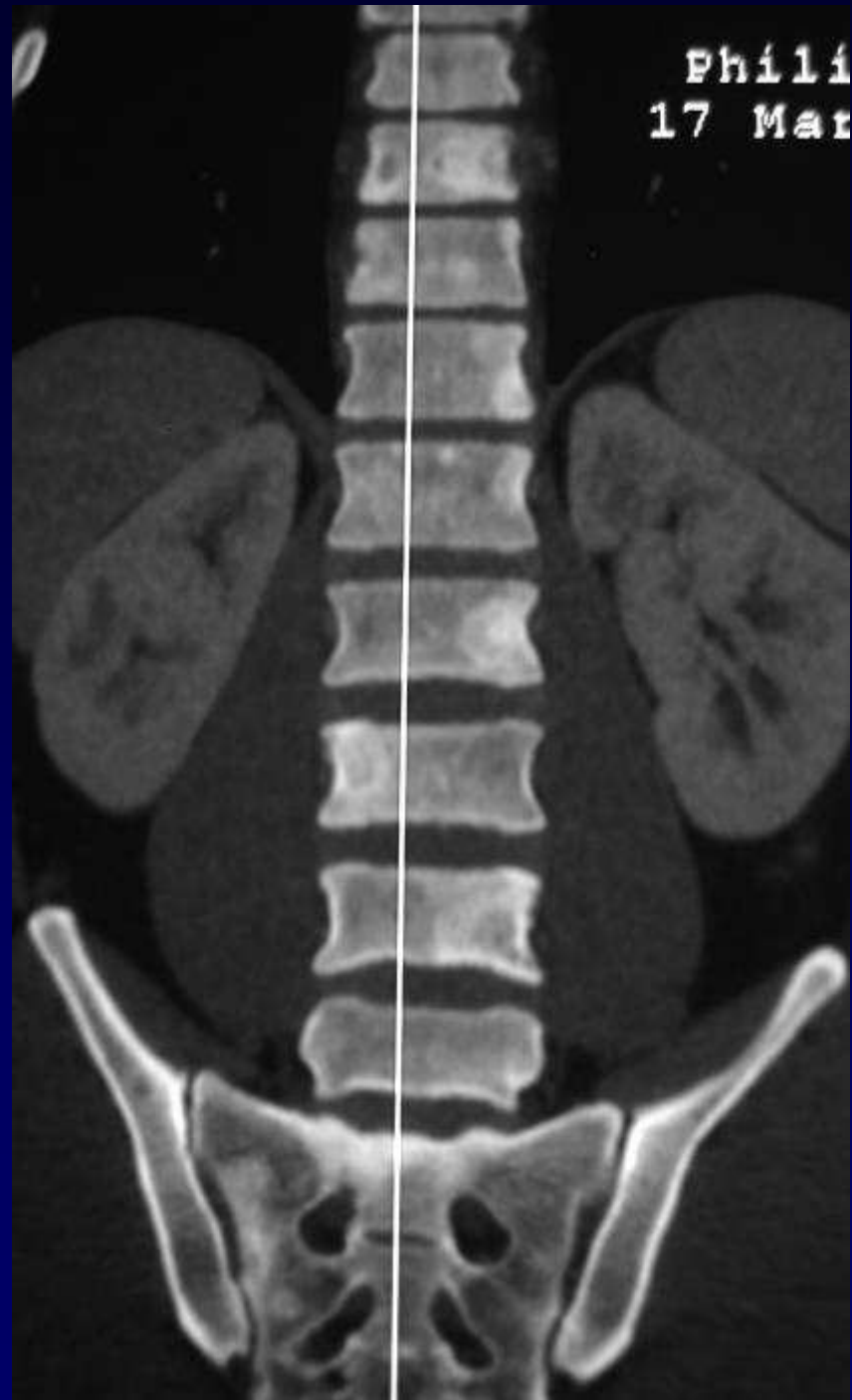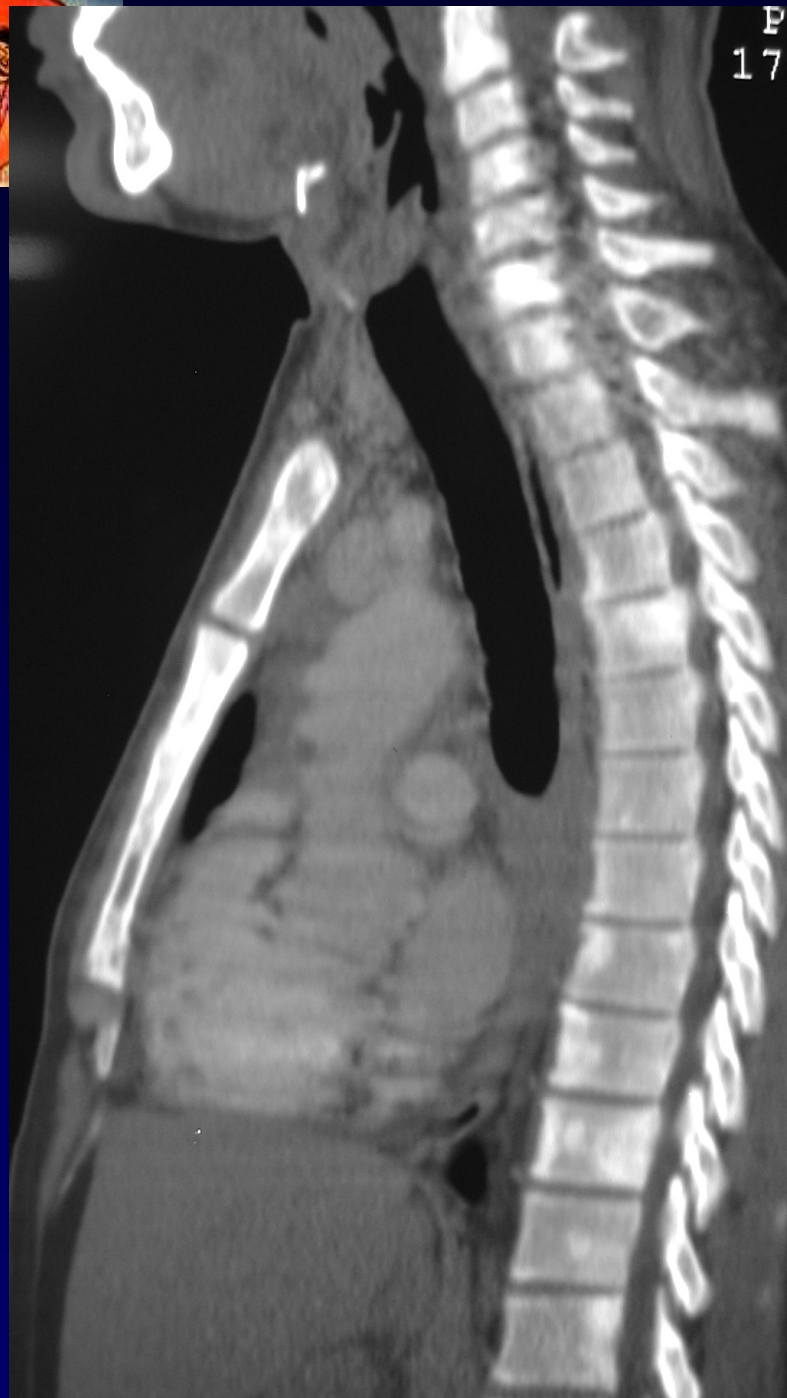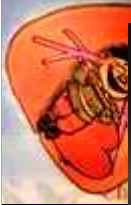ATCD récent d'orchépididymite

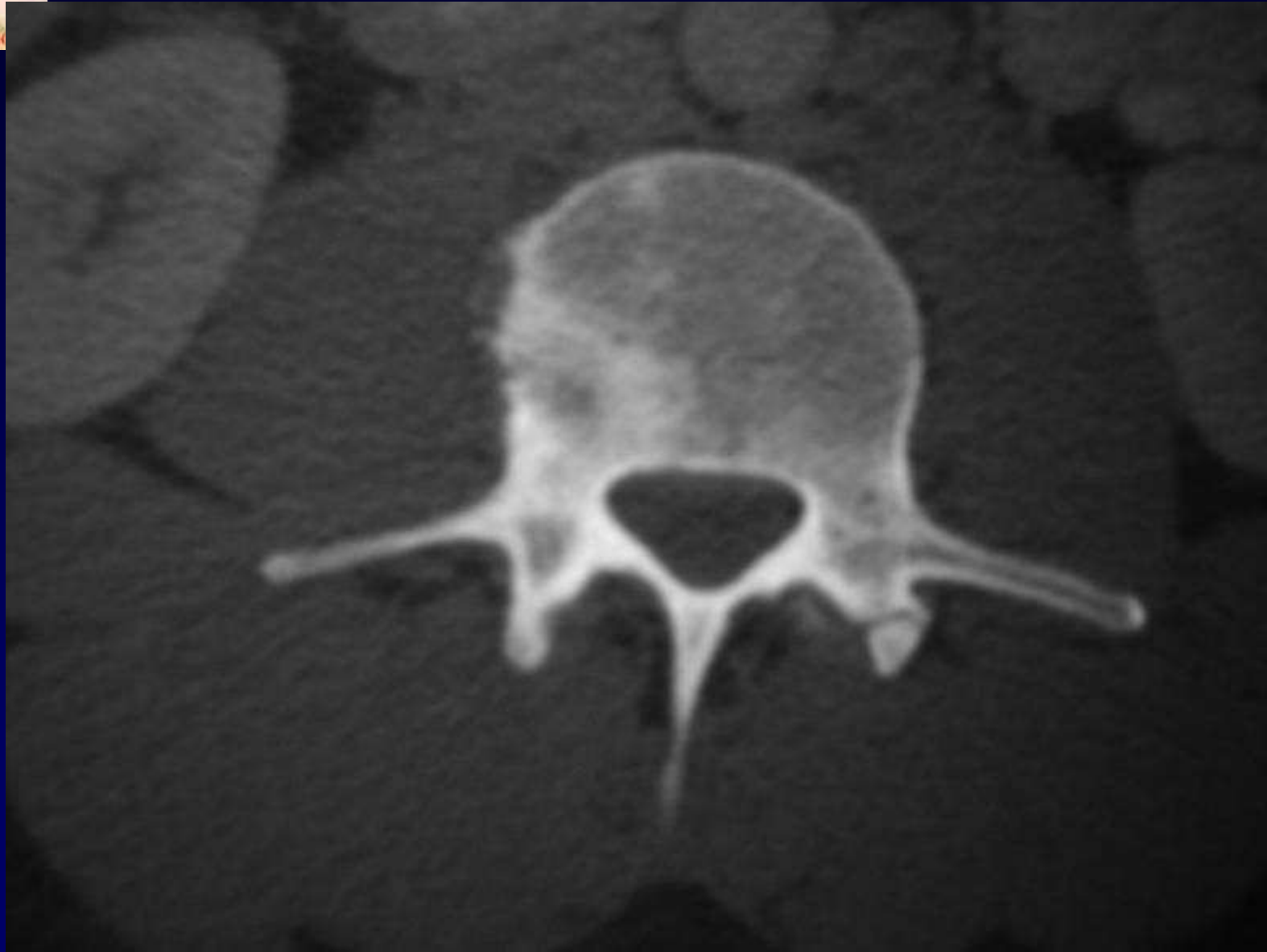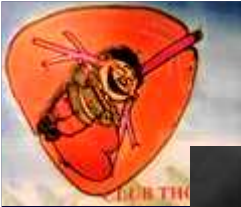Adénomégalias cervicales

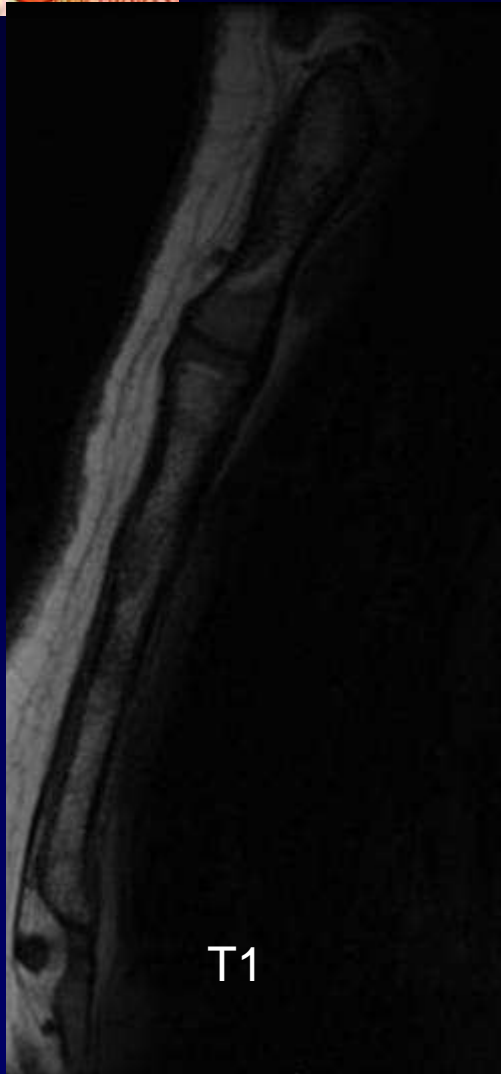
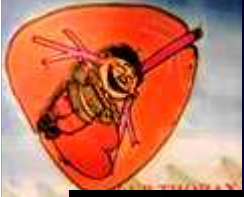


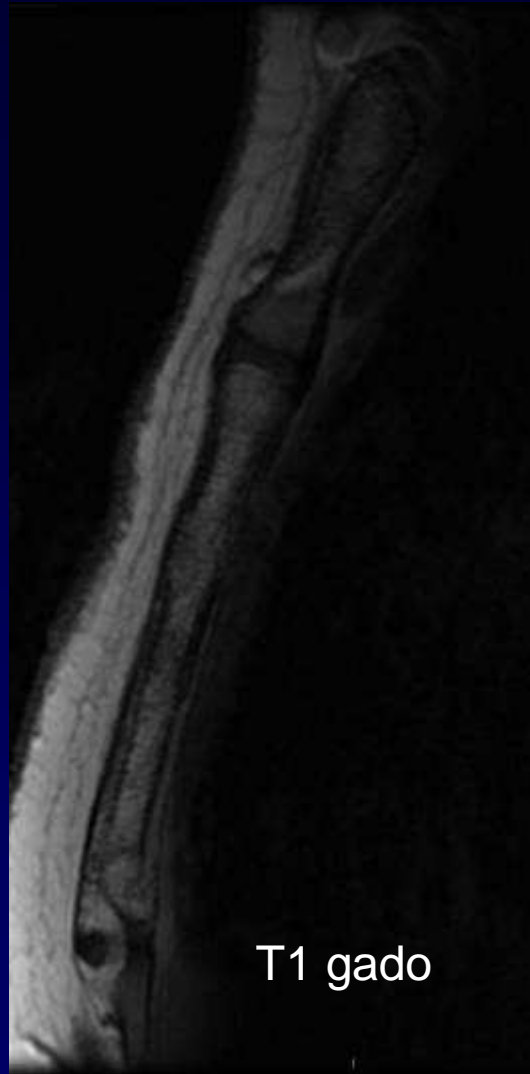
Mars 05



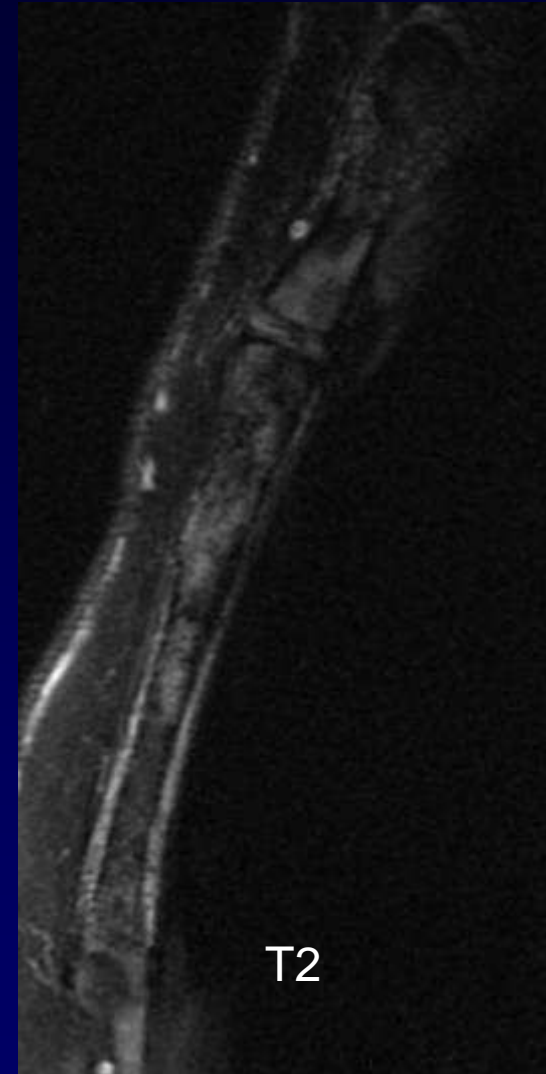




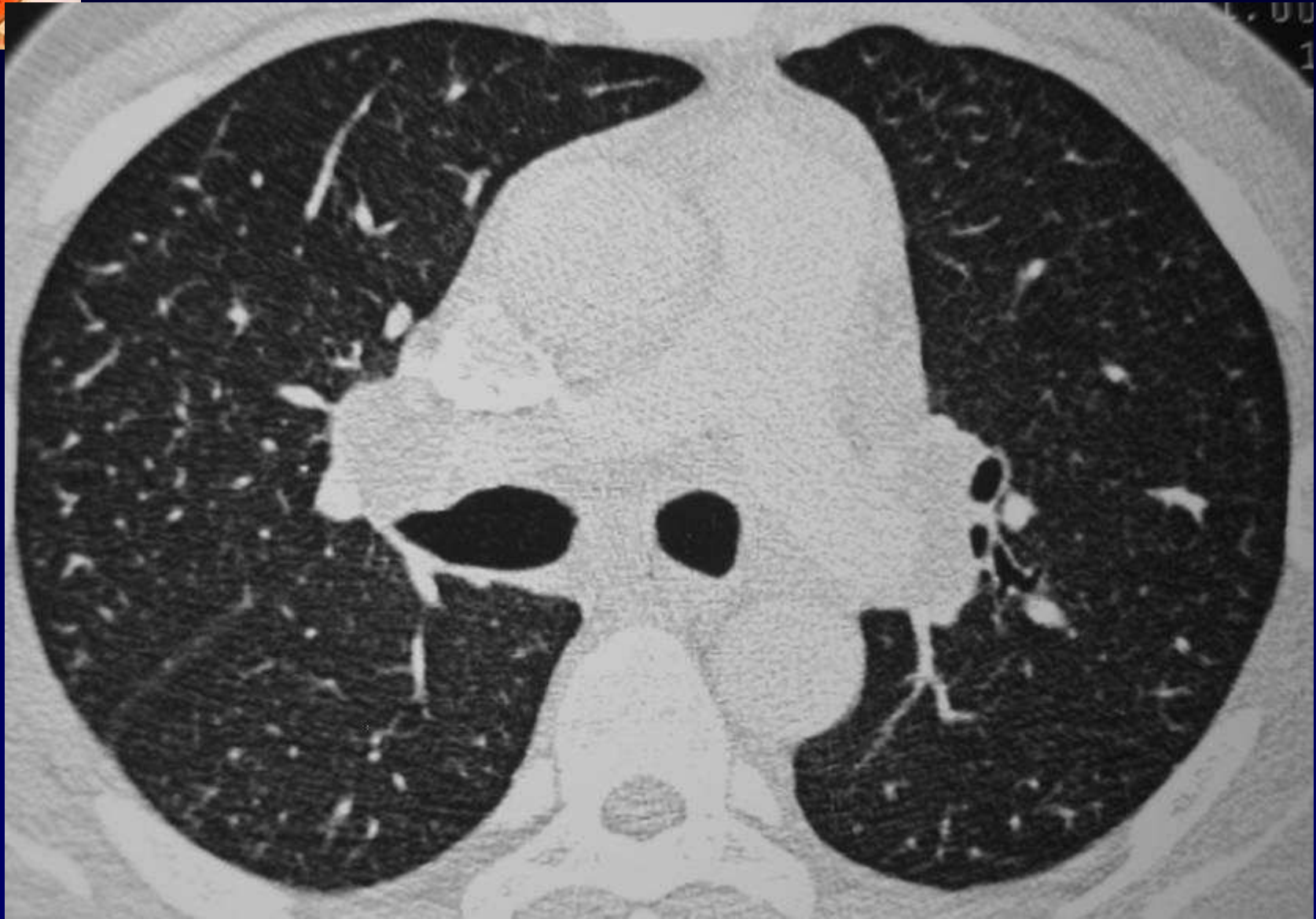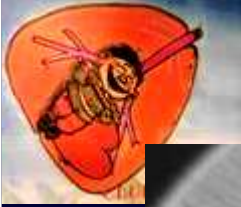T1



T1 gado

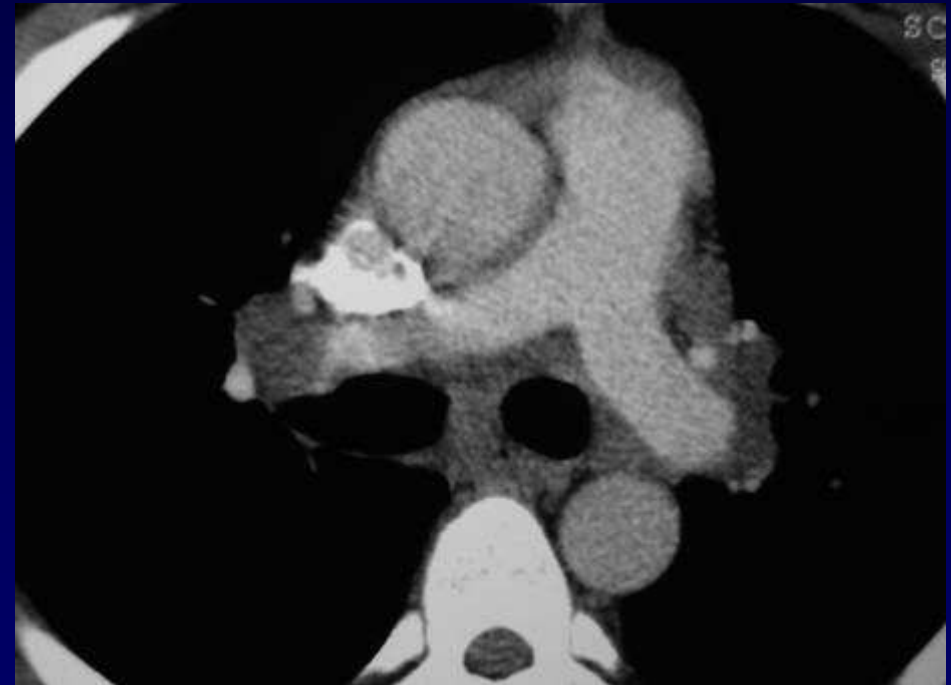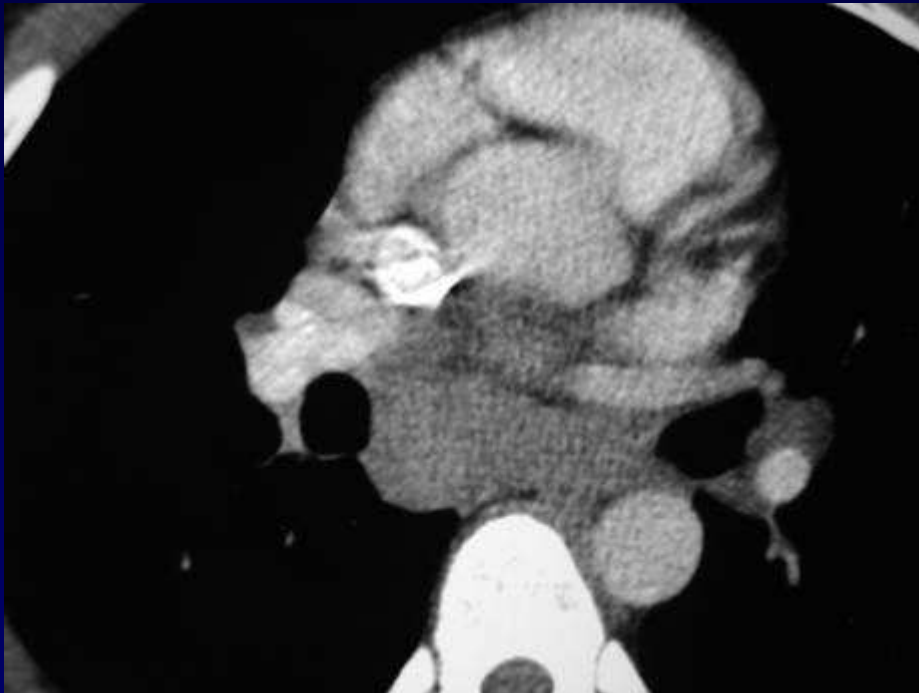


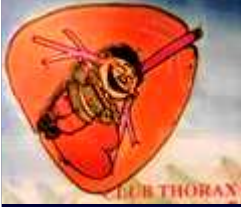T2





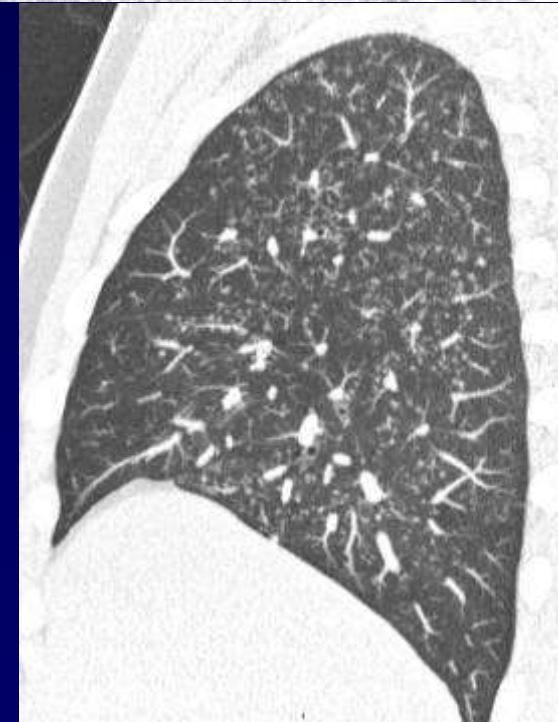
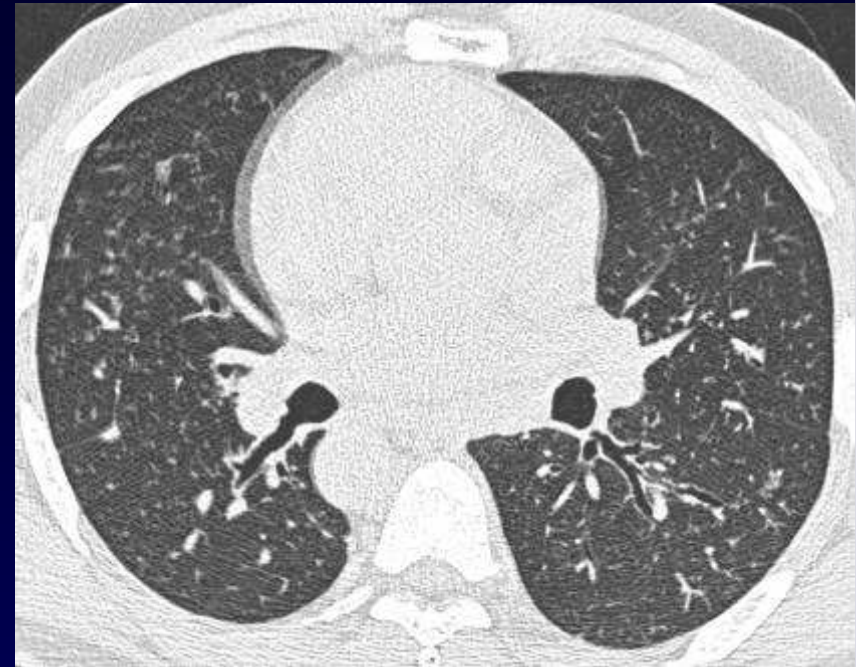
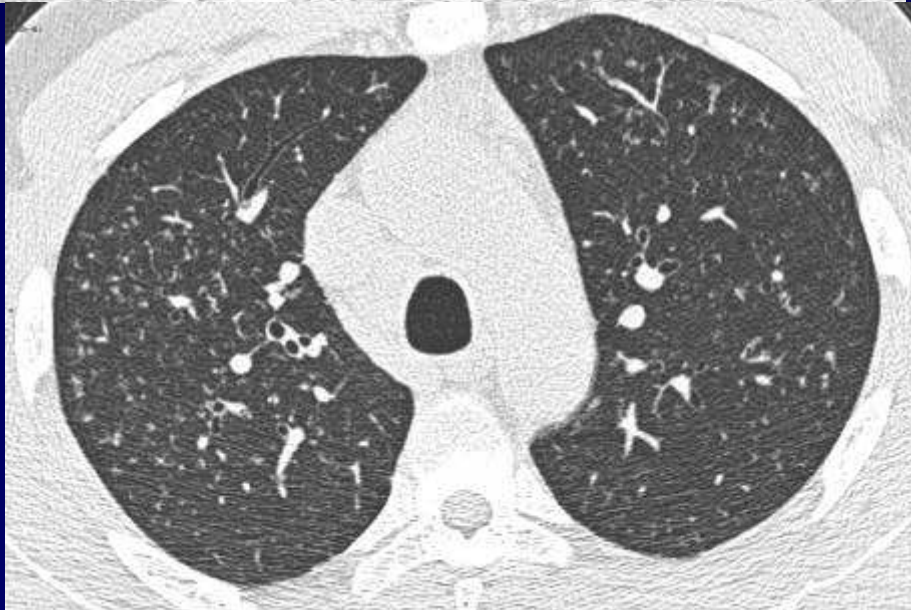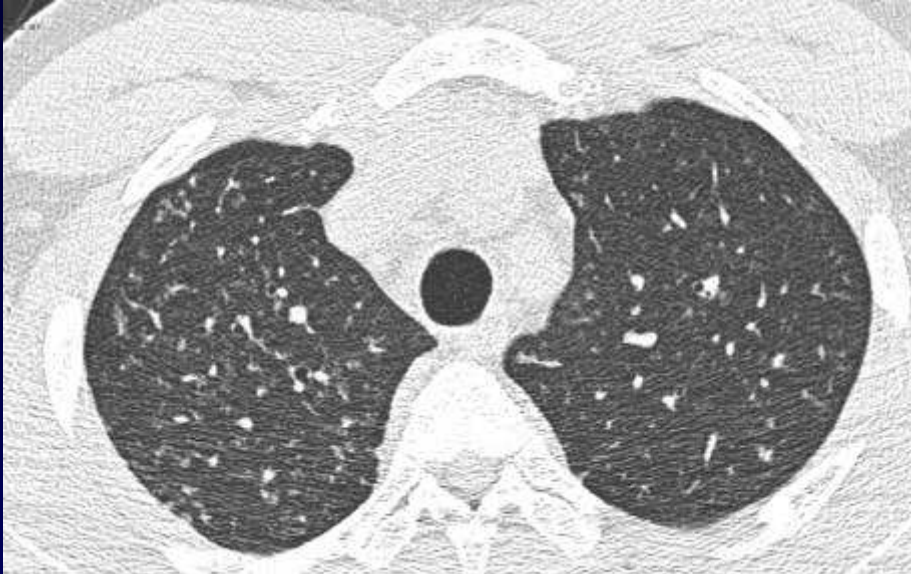Diagnostic ?

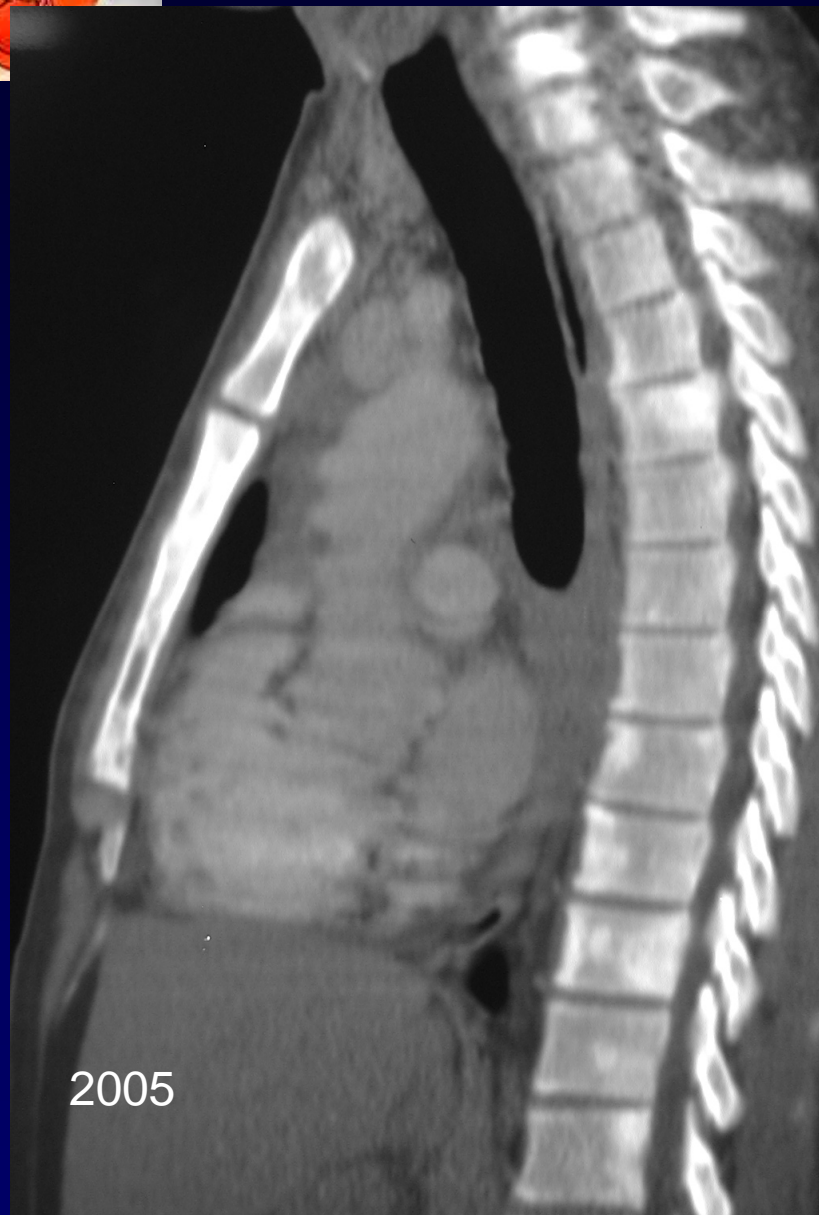




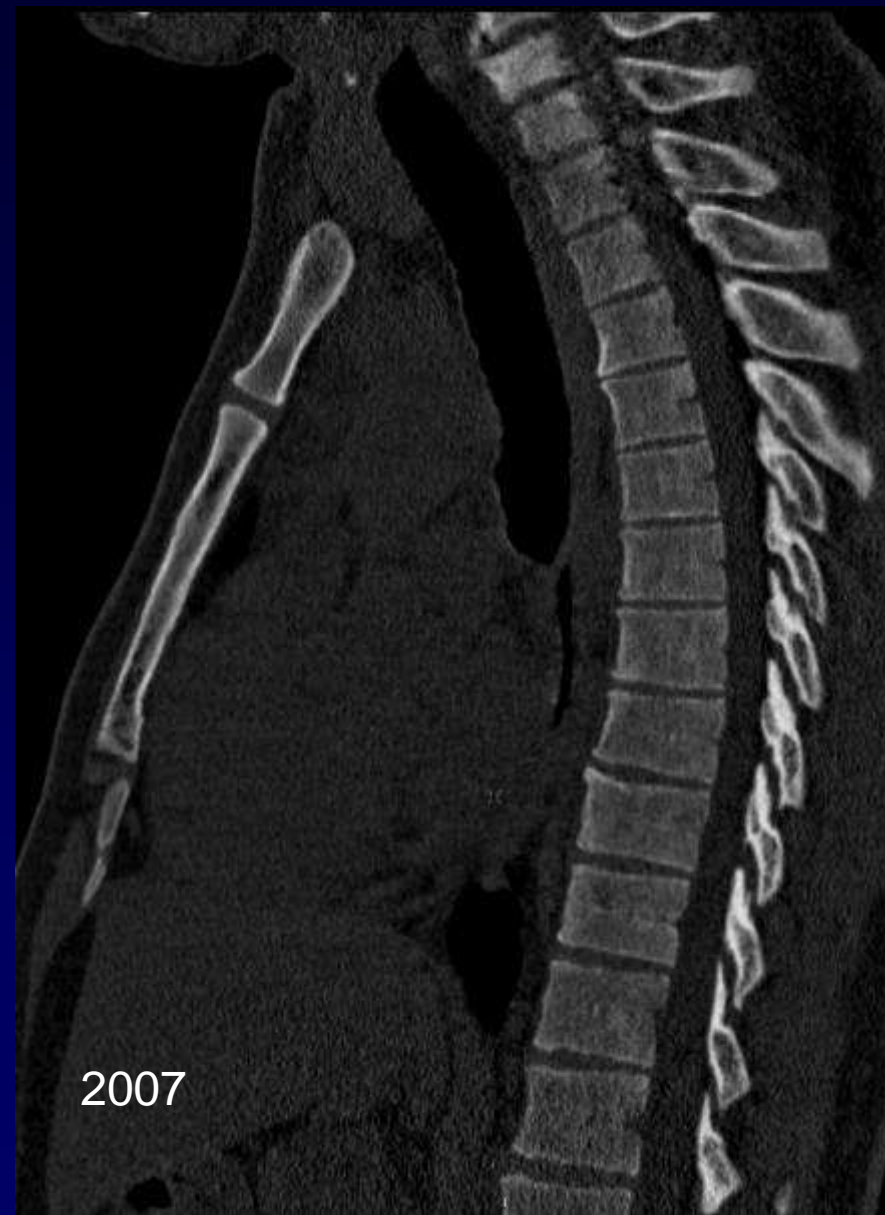Traitement corticoïdes

Contrôle TDM systématique

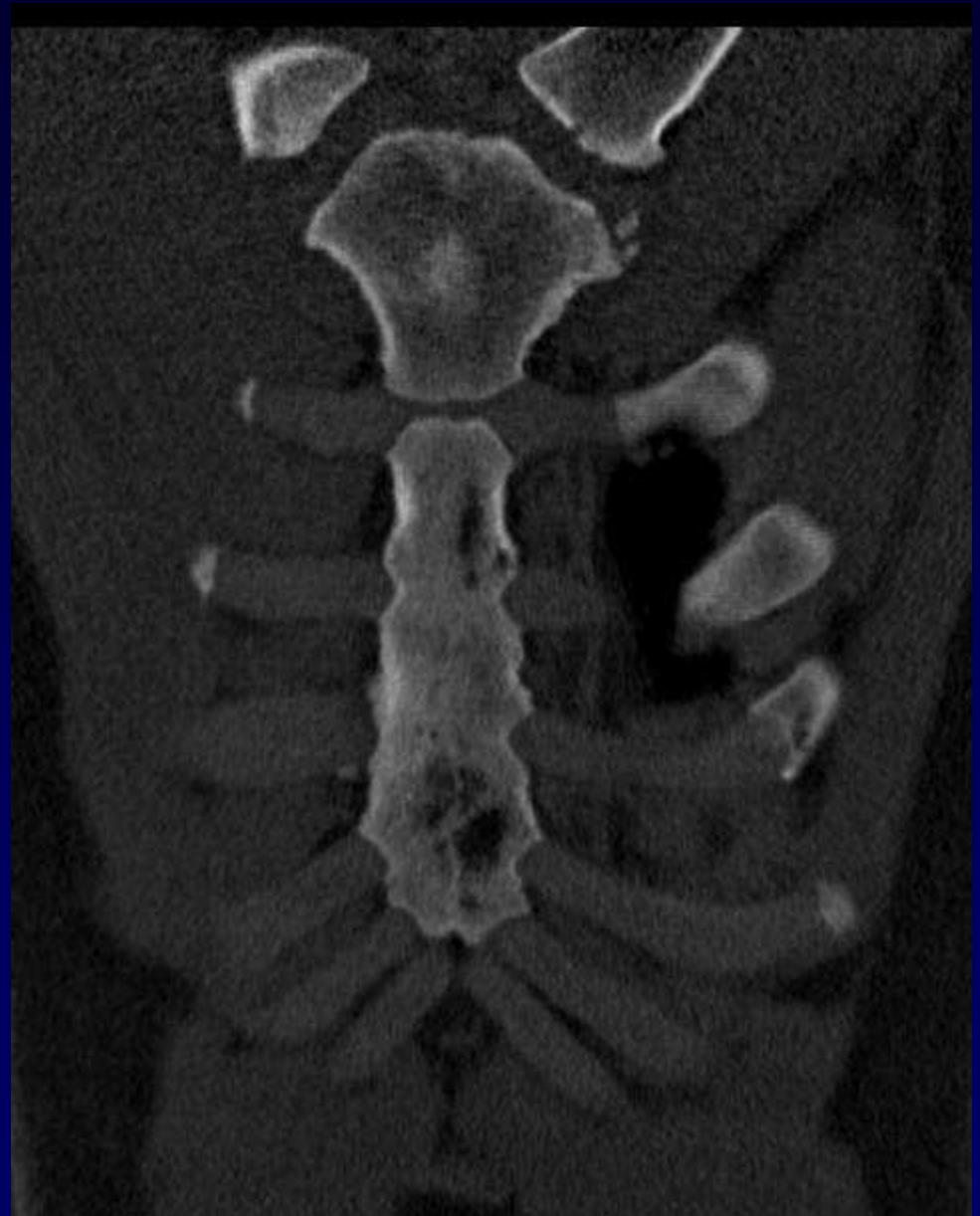
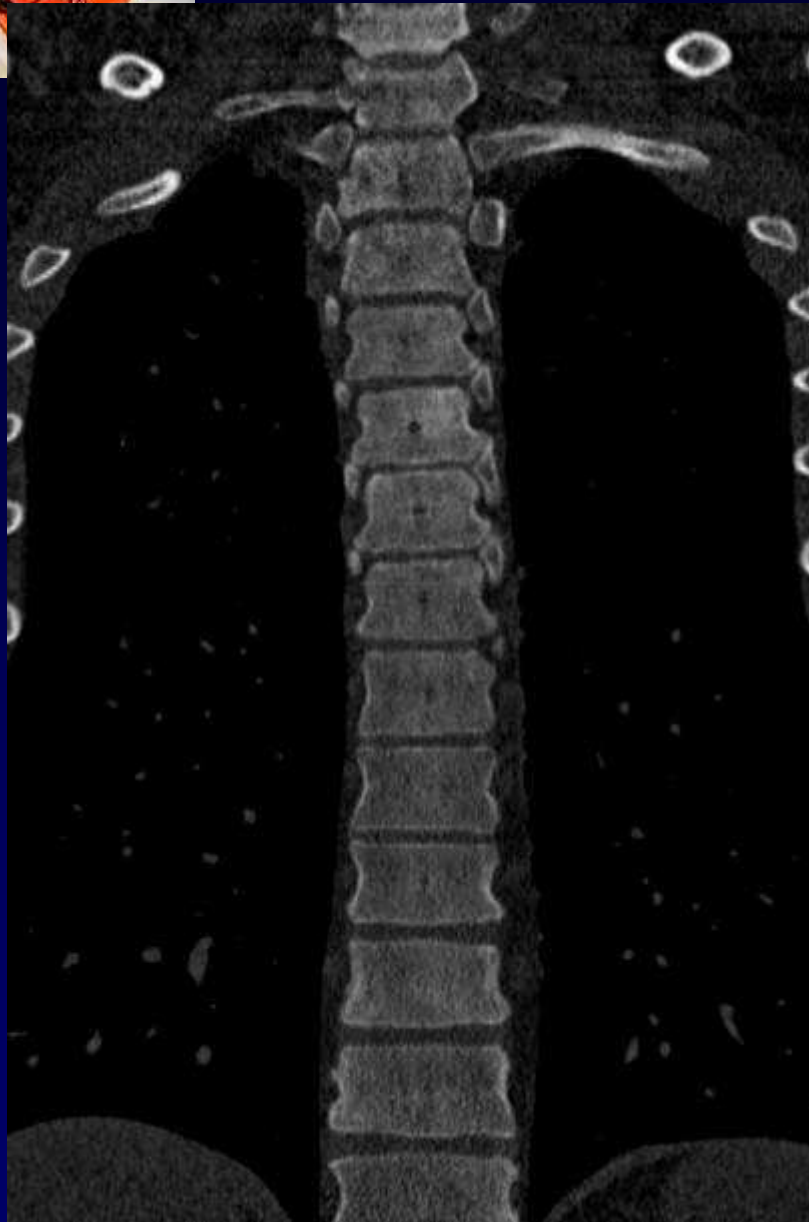
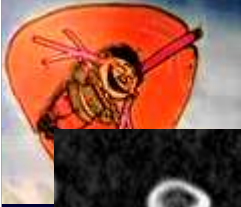

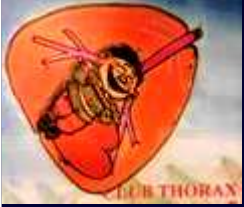2005



2007





Diagnostic

Sarcoidose systémique

Atteinte : médiastino-pulmonaire

osseuse

cervicale

génitale

Codage : Paroi – Poumon - Inflammatoire